

Motor Areas Beyond Motor Performance: Deficits in Serial Prediction Following Ventrolateral Premotor Lesions

Ricarda I. Schubotz, Katrin Sakreida, and
Marc Tittgemeyer

Max Planck Institute of Human Cognitive and Brain Sciences

D. Yves von Cramon

Max Planck Institute of Human Cognitive and Brain Sciences
and University of Leipzig

Previous functional MRI findings have indicated that a premotor–parietal network is involved in the perceptual processing of sequential information. Given that premotor functions have traditionally been restricted to behaviors requiring motor or sensorimotor computations, the goal of the present patient study was to further investigate whether the lateral premotor cortex is critical in purely perceptual sequencing. Patients with either ventral premotor or inferior parietal lesions, in addition to patients with prefrontal lesions and age- and gender-matched healthy controls, were tested during the processing of temporal, object-specific, and spatial sequences. Results revealed that premotor patients as well as parietal patients showed significantly higher error rates than did healthy controls on all sequence tasks. In contrast, prefrontal patients showed no behavioral deficits. These findings support the significance of the ventrolateral premotor cortex, in addition to parietal areas, in nonmotor (attentional) functions.

Recent functional MRI (fMRI) studies have shown that the human ventrolateral premotor cortex (PMv) responds to sensory events, particularly to-be-predicted events (Schubotz, Friederici, & von Cramon, 2000; Schubotz & von Cramon, 2001a, 2001b, 2002a, 2002b, 2002c; Schubotz, von Cramon, & Lohmann, 2003). In line with recent findings in humans (Aziz-Zadeh, Maeda, Zaidel, Mazziotta, & Iacoboni, 2002; Chaminade, Meary, Orliaguet, & Decety, 2001; Hanakawa et al., 2002; Ramnani, Toni, Josephs, Ashburner, & Passingham, 2000) and monkeys (Rizzolatti, Fogassi, & Gallese, 2002), these data suggest that the premotor cortex subserves a variety of behavior that does not necessarily result in motor output. We have proposed that the PMv subserves prospective memory or, in other words, functions as a *forward model* of sequential information. This allows such information to be used in both motor planning and perceptual prediction (i.e., in motor as well as nonmotor behavior).

However, in all of our studies the PMv has been coactivated with parietal areas (i.e., those that have strong reciprocal connections to the PMv, as shown in monkeys; Murata et al., 1997; Murata, Gallese, Kaseda, & Sakata, 1996; Rizzolatti, Fogassi, & Gallese, 2000; Sakata & Taira, 1994; Sakata, Taira, Murata, & Mine, 1995; Taira, Mine, Georgopoulos, Murata, & Sakata, 1990).

Thus, the question arises as to how the functional contributions of lateral premotor areas and parietal areas differ in terms of perceptual prediction.

In the present study, we set out to investigate this question in neurological patients. In a visual serial prediction task (SPT; Schubotz, 1999), behavioral performance was tested among patients with lesions of either ventrolateral premotor or inferior parietal areas. Functional MRI studies have shown that these two regions are activated in temporal, object-specific, and spatial SPTs (Schubotz & von Cramon, 2001a). Therefore, we based selection of patients on our fMRI findings, including only those with lesions inferior to the connection of the superior precentral sulcus and the superior frontal sulcus (premotor patients) or within the inferior parietal lobule (parietal patients). Both prefrontal control patients and age- and gender-matched healthy controls were tested. Lesions among the prefrontal patients were mainly restricted to the frontopolar region, excluding lesions among the premotor patients. Patients and controls completed (a) an SPT involving temporal rhythm sequences, object sequences, and spatial position sequences and (b) a nonprediction control task. We expected premotor patients to be generally impaired in serial prediction, and we expected patients with parietal lesions to show deficits in object sequences and spatial sequences but not in rhythm sequences. Prefrontal patients were expected to exhibit no impairment.

Ricarda I. Schubotz, Katrin Sakreida, and Marc Tittgemeyer, Department of Neurology, Max Planck Institute of Human Cognitive and Brain Sciences, Leipzig, Germany; D. Yves von Cramon, Department of Neurology, Max Planck Institute of Human Cognitive and Brain Sciences, and Day Clinic of Cognitive Neurology, University of Leipzig, Leipzig, Germany.

The Max Planck Institute of Human Cognitive and Brain Sciences was formerly the Max Planck Institute of Cognitive Neuroscience.

Additional materials are on the Web at <http://dx.doi.org/10.1037/0894-4105.18.4.638.supp>.

We thank Heike Jänicke, Corinna Koßack, Sonja Kotz, Anke Pitzmaus, and Uta Wolfensteller for their contributions.

Correspondence concerning this article should be addressed to Ricarda I. Schubotz, Department of Neurology, Max Planck Institute of Human Cognitive and Brain Sciences, Leipzig, Germany. E-mail: schubotz@cbs.mpg.de

Method

Patients and Control Participants

Twenty-one patients of the Day Clinic of Cognitive Neurology at the University of Leipzig participated in the study after providing informed consent. The experimental standards were approved by the local ethics committee of the University of Leipzig. Depending on lesion site, patients were grouped as premotor ($n = 7$; 3 female, 4 male; mean age = 50.1 years), parietal ($n = 7$; 2 female, 5 male; mean age = 50.2 years), or prefrontal ($n = 7$; 3 female, 4 male; mean age = 39.7 years). Healthy controls, matched with each patient group for age and gender (premotor control: $n = 7$, mean age = 49.4 years; parietal control: $n = 7$, mean age = 49.7 years; prefrontal control: $n = 7$, mean age = 39.2 years), were also tested.

Table 1 presents data on demographic and lesion characteristics for each patient. All patients were classified as chronic, and average amounts of time since lesion were 32.8 months among premotor patients, 51.7 months among parietal patients, and 79.2 months among prefrontal patients. Lesion sites were determined by T1-weighted MRI scans. Lesions among the premotor patients mainly resulted from infarctions of the precentral sulci artery or the posterior prefrontal artery; lesions among the parietal patients were typically the result of infarctions of the parietal branches of the middle cerebral artery.

On the basis of suggested functional homologies between nonhuman primates and humans, researchers have proposed that the border between the ventral and dorsal premotor cortex is near the level of the superior frontal sulcus (roughly referring to axial level $z = 50$ of the

stereotactic frame of Talairach & Tournoux, 1988; see Rizzolatti et al., 2002). Following this suggestion, we ensured that none of our premotor patients' lesions fell into the dorsal or medial premotor cortex. Registered to Talairach space, lesions extended axially to maximal $z = 46$ in the premotor group and to $z = 43$ in the parietal group. Two premotor patients (PMC1 and PMC4) suffered from mild speech apraxia. Two premotor (PMC1 and PMC7) and 3 parietal (PAR3, PAR5, and PAR7) patients had discrete or stronger hemiparesis. Two parietal patients (PAR4 and PAR5) had hemianopia and lower quadranopia. Prefrontal (FRO) patients had lesions of different etiology that were located in the frontomedian, frontopolar, frontobasal, or frontolateral areas. Lesion volumes were approximately 16.2 ml among premotor patients, 26.1 ml among parietal patients, and 42.4 ml among prefrontal patients. Note

Table 1
Patient Demographic and Clinical Data

Patients	Gender	Age (years)	TSL (months)	H	Etiology	Site of lesion	Acute deficit(s)	Persistent deficit(s)
Premotor patients								
PMC1	F	58	71	L	MCAI	Lateral frontal, anterior insula, striatum	None	Speech apraxia
PMC2	M	53	51	R	MCAI	Lateral frontal, striatum	Executive dysfunction, global attentional deficit	Hemiparesis
PMC3	M	41	48	L	AVM	Lateral frontal	None	Nonaphasic communication disorder
PMC4	M	61	14	L	MCAI	Lateral frontal	None	Speech apraxia, dysphasia
PMC5	F	71	13	L	MCAI	Lateral frontal	Dysphasia	None
PMC6	F	49	22	R	MCAI	Lateral frontal	Executive dysfunction, global attentional deficit	None
PMC7	M	18	11	L	MCAI	Lateral frontal, striatum	None	Dysphasia, discrete hemiparesis
Parietal patients								
PAR1	M	53	43	L	MCAI	Inferior parietal	Dyslexia, dysgraphia, dyscalculia	None
PAR2	F	70	44	L	MCAI	Inferior parietal, posterior insula	Dysphasia	None
PAR3	F	50	57	L	MCAI	Inferior parietal	Dysphasia, dyscalculia	Hemiparesis
PAR4	M	55	144	R	MCAI	Inferior parietal	None	Hemineglect, hemianopia
PAR5	M	39	28	R	MCAI	Inferior parietal	Global attentional deficit, visuospatial impairment	Quadrantopia, hemiparesis
PAR6	M	26	31	L	VI	Temporoparietal, posterior insula	Dyslexia, dysgraphia, dyscalculia	None
PAR7	M	59	15	L	MCAI	Inferior parietal	Dyslexia, dysgraphia, dyscalculia	Discrete hemiparesis
Prefrontal patients (clinical control)								
FRO1	M	28	65	B	TBI	Ventromedial prefrontal	Executive dysfunction, anosmia	None
FRO2	F	41	49	R	ACOA	Posterior orbital basal forebrain	Apathy, memory dysfunction	None
FRO3	F	51	104	B	TUM	Ventromedial	Executive dysfunction, anosmia	None
FRO4	M	41	249	B	TBI	Ventromedial	Acquired sociopathy, executive dysfunction, hyposmia	None
FRO5	F	40	22	L	ACOA, ACAI, MCAI	Frontobasal, striatum	Apathy, executive dysfunction, memory dysfunction	None
FRO6	M	30	20	R	TBI	Ventromedial prefrontal	Apathy, executive dysfunction	None
FRO7	M	47	46	B	TBI	Ventromedial	Acquired sociopathy	None

Note. PMC = premotor patients; F = female; M = male; TSL = time since lesion; H = hemisphere of lesion; L = left; R = right; B = bilateral; MCAI = middle cerebral artery infarction; AVM = arteriovenous malformation; PAR = parietal patients; VI = venous infarction; FRO = prefrontal patients; TBI = traumatic brain injury; TUM = tumor/meningioma; ACOA = anterior communicating artery aneurysm; ACAI = anterior cerebral artery infarction.

that these considerable between-volumes differences favored the to-be-rejected hypothesis (i.e., no impairment among premotor patients).

To enhance a comparison of respective lesion locations, we performed a lesion registration. Lesion areas were segmented manually by a neurology expert, and resulting segmented lesions were overlaid onto a template brain. For this purpose, we applied the following mapping procedure. Initially, we aligned the T1-weighted MRI scans for each patient with the chosen template brain image using an affine transformation (i.e., including translation, rotation, and scaling). We then used the respective transformation matrices to warp each segmented lesion onto the template. Routines are described in more detail in Jänicke et al. (2002). Note that the resulting overlaid images (see Figure 1) were not controlled for interindividual variances in sulci and gyri. Thus, a certain amount of distortion within the overlaid images has to be taken into consideration. The magnitudes of distortion could also differ among the three patient groups, in that structural differences increase from posterior to frontal brain sites. Therefore, individual T1-weighted MRI scans for each patient are also depicted in Figure 1.

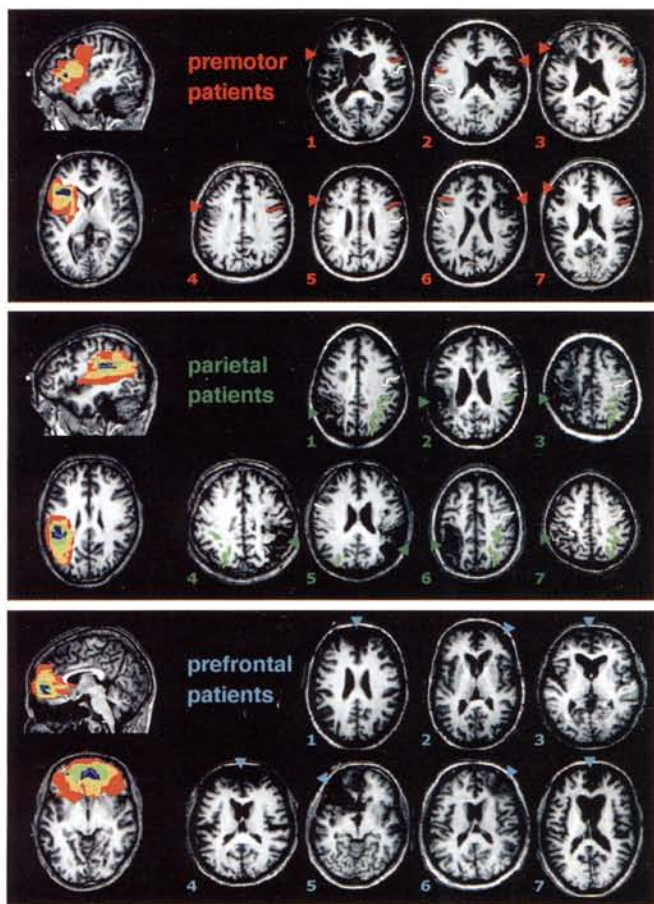


Figure 1. Representative axial slices of T1-weighted MRI scans for premotor, parietal, and prefrontal patients. Numbers correspond to the identification numbers shown in Table 1. Lesion sites are indicated by triangles. The following sulci are highlighted in the intact hemisphere to provide better orientation: central sulcus (white), inferior precentral sulcus (red), and intraparietal sulcus (green). In addition, overlays are shown for each patient group, with red indicating minimum overlap and blue indicating maximum overlap.

Materials and Tasks

Stimulus examples are shown in Figure 2 (a color version of Figure 2 is on the Web at <http://dx.doi.org/10.1037/0894-4105.18.4.638.supp>). Nine stimuli were used in the experiment. Each stimulus consisted of a gray circle 35 mm in diameter with a geometrical form (circle, triangle, or square) placed in its center; these forms were of different colors (red, blue, or yellow). On each screen, two identical objects were presented at opposite locations on a virtual circle. An advantage of the rotating-twin stimulation adapted from Schubotz and von Cramon (2001a) is that it can be used for patients who have unilateral visual field defects (as did 2 patients in our parietal group). Resulting spatial processing deficits (Vallar, 1993) are compensated for by presenting the relevant information doubly on both the right and left sides of fixation, with two identical objects at opposite locations of a virtual circle on the screen center. Overall, there were six possible positions at constant gaps of 60°. The screen center was marked by a small fixation square to facilitate constant visual fixation. Thirty-six trials were presented in each task in a block design. Each trial lasted 8.85 s, and the intertrial interval was 5.7 s. Although tasks were presented in separate blocks, each trial started with a visual cue that reminded patients which task had to be performed next. Within each trial, 12 pictures were presented successively for a mean duration of 600 ms each; the interstimulus interval was 150 ms.

Three SPT conditions and a control task were used in the experiment. In the SPT conditions, the first two pictures within each trial built a sequential pattern that was repeated six times within the same trial. Patients and controls were asked to attend only to a task-relevant stimulus property: presentation duration, object, or spatial location. They were instructed to memorize the task-relevant feature of the first two pictures (starting sequence) and to indicate whether this pattern reappeared five times within the same trial. In the rhythm task, they were instructed to attend to the temporal pattern associated with the presentation duration of the starting sequence. This duration pattern could either be 300 ms/900 ms or 900 ms/300 ms. In the object task, the order of the two objects presented in the starting sequence was the focus (e.g., blue square/red triangle or yellow circle/red square). In the position task, participants were instructed to attend to the order of the spatial locations of the objects in the starting sequence (e.g., 120°/0° or 0°/60°). To minimize the influence of task-irrelevant properties, pictures were presented for 600 ms each in an isochronous rhythm in both the object and position conditions. Within all SPT conditions, object and position properties varied in an ABAB manner, as depicted in Figure 2. This made it easier for patients to orient themselves within the ongoing sequence presentation.

In the SPT conditions (rhythm, object, and position), performance was tested in a forced-choice response mode. In 50% of the trials, on the 10th or 11th picture the task-relevant stimulus property was transferred to the end of the trial, and thus sequential order was violated for the task-relevant property. In these violation trials, the subsequent picture(s) moved up so that no gap was perceived. Participants had to indicate, by pressing a button, whether a deviant was (right button) or was not (left button) present in the trial. Patients were allowed to respond with their preferred hand. Responses could be made either immediately after detection of a deviant or up to 3 s after the end of the stimulus sequence. Visual feedback was provided indicating whether the answer was correct (indicated by a plus sign) or incorrect (indicated by a minus sign). In addition, a nonsequential task was used to control for perceptual requirements and motor responses. In this control task, the same type of stimulus was used as in the SPT conditions, with the starting sequence being repeated five times in an isochronous rhythm. Patients and control participants attended to a gray target stimulus presented on the 10th or 11th picture in 50% of the control trials. After stimulus presentation, participants had to indicate whether a target was present (right button) or absent (left button). Note that no serial prediction was required for successful performance in the control task.




Figure 2. Examples of stimulus presentation in the rhythm, object, and position serial prediction tasks (SPTs) and in the baseline task. The presentation time (in milliseconds) of each picture is shown at the bottom of each sequence. All SPT examples show deviant trials, with the deviant picture shown in the next to last frame. The baseline task example shows a trial containing the predefined target, also shown in the next to last frame. For task details, see the Method section. A color version of this figure is on the Web at <http://dx.doi.org/10.1037/0894-4105.18.4.638.suppl>.

Procedure

Participants received instructions and were briefly trained before the experimental session. They were comfortably seated about 1 m in front of the presentation screen, with the index and middle fingers of their response hand positioned on the response buttons. They were told to pause if they felt tired and to terminate the session at any time if necessary. The entire experimental session lasted about 30 min and was continuously supervised.

Results

Behavioral performance was assessed by means of error rates (see Figure 3). Reaction times were not analyzed so as to exclude effects resulting from unspecific behavioral impairments (e.g., slowing). The small number of time-outs indicated that patients were given enough time to answer. Time-outs were distributed as follows: premotor patients, 0% (premotor controls, 1.4%); parietal patients, 4.2% (parietal controls, 0.7%); and prefrontal patients, 2.1% (prefrontal controls, 2.1%). Averaged across all SPT conditions, results (*t* tests for independent samples) showed that patients with hemiparesis were not more affected than those without motor deficits, $t(12) = -0.59$, $p = .565$. Premotor patients with hemiparesis made 2.8% fewer errors than those without hemiparesis (11.6% vs. 14.4%, respectively), and parietal patients with hemiparesis made 6.7% more errors than those without hemiparesis (18.5% vs. 11.8%, respectively). These findings indicate

that motor deficits have no significant impact on behavioral performance on the SPT.

Owing to the small sample size, the performance levels of patients with mild speech apraxia (average SPT error rate of 16.2%, as compared with 12.6% for the other 5 premotor patients) could not be compared statistically. However, a descriptive analysis supported the finding that there were no outliers in the premotor or parietal patients' performance scores. We therefore suggest that the higher error rate (3.6% more errors) observed among the premotor patients with apraxia than among those without apraxia cannot be interpreted as reflecting a specific interaction between mild apraxia and SPT performance. Finally, the 2 parietal patients with constricted visual fields showed no specific impairment in the spatial SPT condition (both primarily made errors on the rhythm task).

Error rates were normally distributed in each task and for each group, as assessed with Kolmogorov-Smirnov tests (which could not be performed for the baseline task in the case of either the premotor or the prefrontal control group because there were no errors in these groups). We conducted three repeated measures analyses of variance (ANOVAs) with the two-level factor task (SPT [collapsed across subconditions] vs. baseline task) and the two-level between-subjects factor lesion (patients vs. controls).

For the premotor patients, analyses indicated a main effect of

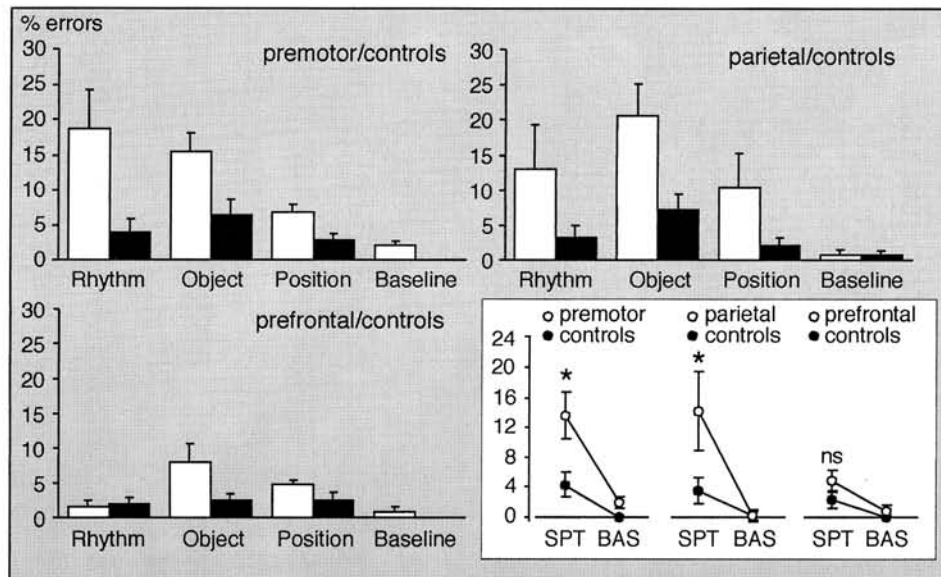


Figure 3. Study results. Performance was assessed by means of error rate percentages. Top left, bottom left, and top right: Behavioral results. Open bars show performance of the premotor, parietal, and prefrontal patients in the three types of serial prediction task (SPT; temporal rhythm, object, and spatial position sequences, respectively) and in the baseline target detection task. Corresponding solid bars represent the performance of the respective healthy controls. Bottom right: Lesion \times Task interactions, which were significant at $p < .01$ (as indicated with asterisks) for the premotor and parietal patients and their respective controls but were not significant for the prefrontal patients. Thus, premotor and parietal patients showed a specific behavioral deficit in serial prediction, whereas performance in the baseline task (BAS) was preserved. Error bars represent percentages of error.

task, $F(1, 12) = 29.51, p < .0001$; a main effect of lesion, $F(1, 12) = 32.55, p < .0001$; and a Task \times Lesion interaction, $F(1, 12) = 6.09, p = .03$. Because of our small sample size, we used a nonparametric method to further analyze this interaction. A Wilcoxon test (for dependent samples) revealed that premotor patients ($z = -2.36, p = .018$) as well as controls ($z = -2.36, p = .018$) made significantly more errors on the SPT than on the baseline task. Furthermore, a Mann-Whitney U test (for independent samples) showed that the performance of premotor patients and that of premotor controls differed significantly on the SPT ($U = 3.00, p = .004$) but not on the baseline task ($U = 10.50, p = .073$). This finding indicates that premotor patients are impaired in serial prediction.

Among the parietal patients, the same analysis yielded a main effect of task, $F(1, 12) = 20.29, p = .001$; a main effect of lesion, $F(1, 12) = 8.48, p = .013$; and a Task \times Lesion interaction, $F(1, 12) = 7.68, p = .017$. A step-down analysis of the interaction revealed the same pattern of results as in the premotor groups and, hence, specific impairment in serial prediction. Both parietal patients and their controls made significantly more errors on the SPT than on the baseline task (parietal patients: $z = -2.36, p = .018$; parietal controls: $z = -1.94, p = .051$). Parietal patients and controls differed significantly on the SPT ($U = 6.00, p = .017$) but not on the baseline task ($U = 22.00, p = .805$).

Finally, among the prefrontal patients, the ANOVA yielded a main effect of task, $F(1, 12) = 29.99, p < .0001$; no main effect of lesion, $F(1, 12) = 2.63, p = .131$; and no Task \times Lesion interaction, $F(1, 12) = 2.29, p = .156$.

In a final analysis, main effects of task were analyzed among premotor and parietal patients and their respective controls. We

conducted a repeated measures ANOVA comprising the three-level factor property (rhythm, object, or position) and the two-level factor lesion (patients vs. controls). For both the premotor and parietal groups, this analysis yielded a main effect of lesion, $F(1, 12) = 15.17, p = .002$, and $F(1, 12) = 8.62, p = .012$, respectively; no main effect of property, $F(2, 24) = 2.82, p = .110$, and $F(2, 24) = 2.40, p = .112$, respectively; and no Task \times Lesion interaction, $F(2, 24) = 1.50, p = .245$, and $F(2, 24) = 0.26, p = .773$, respectively.

Taken together, these results point to impaired serial prediction performance on the part of both the premotor and parietal patients but not the prefrontal patients. Although all of the groups (including the healthy controls) had more difficulty with the SPT than with the baseline task, the significant Lesion \times Task interactions in the premotor and parietal groups (but not in the prefrontal group) indicate that these two groups were specifically impaired in serial prediction (see Figure 3, bottom right). Moreover, the final analysis revealed that, among both the premotor and parietal patients, the SPT performance deficit was not dependent on the attended stimulus property.

Discussion

In the present study we investigated, by means of a visual SPT, whether ventrolateral premotor lesions result in serial prediction deficits. This task allowed us to test the functional significance of premotor and parietal cortices that have been shown to be robustly coactivated during serial prediction in previous fMRI studies (Schubotz & von Cramon, 2001a, 2001b, 2002a, 2002b, 2002c; Schubotz et al., 2003). In accord with our expectations, premotor

patients showed significant deficits on the SPT. This impairment did not depend on the stimulus property to which patients attended but resulted from the temporal, object-related, and spatial prediction to which they had to adhere. Parietal patients were likewise impaired in serial prediction. The clinical control group with prefrontal lesions, on the other hand, showed no deficits at all. This outcome further confirms that both the ventrolateral premotor and corresponding parietal areas are critical in serial prediction, as previously reported in a series of fMRI studies.

The present study contributes to the view that processing of perceptual events relies on premotor processes, even if no motor output is required. In contrast to other premotor areas, the PMv seems to involve the coding and transcoding of sensory features. Generally, premotor lesion studies in humans and monkeys have focused on the dorsal premotor cortex and the supplementary motor area (SMA); lesions restricted to the PMv have rarely been explored. Findings in monkeys indicate that the PMv and dorsal premotor cortex contribute differently to sensorimotor transformation. The dorsal premotor cortex is relevant for the selection of a particular movement on the basis of visual cues that provide an abstract sensorimotor transformation instruction (i.e., conditional tasks; Kurata & Hoffman, 1994; Passingham, 1985, 1988). In contrast, the PMv is involved whenever tactile or visual information is needed to guide the interaction of the body with an object (i.e., reaching, grasping, and manipulating; Fogassi et al., 2001; Gregoriou & Savaki, 2003; Schieber, 2000). This is in line with results indicating that the PMv contains a high ratio of neurons with sensory receptive fields. Because these are frequently registered by different body parts, the PMv is taken to code environmental features as a reference frame for a particular set of effectors (Fogassi et al., 1996).

A crucial characteristic of the SPT paradigm used in the present study is its anticipatory requirements or, in other words, *sequencing functions*. Perceptually comparable tasks without this requirement, such as demanding serial match-to-sample tasks (Schubotz & von Cramon, 2002b) and target detection in stimulus sequences (as used as control conditions in other SPT studies), have not been shown to activate the PMv in fMRI studies. Likewise, sequencing functions are required in the "motor version" of the SPT, the serial reaction task (Nissen & Bullemer, 1987). This task has also been reported to engage the lateral premotor cortex (Gordon et al., 1995; Grafton, Hazeltine, & Ivry, 1995; Hazeltine, Grafton, & Ivry, 1997; Hikosaka, Miyashita, Miyachi, Sakai, & Lu, 1998; Hikosaka et al., 1996; Honda et al., 1998; Sadato, Campbell, Ibanez, Deiber, & Hallett, 1996; Sakai et al., 1998; Toni, Krams, Turner, & Passingham, 1998). Thus, premotor activation appears to be caused by the processing of stimulus sequences rather than by the transformation of those sequences into a corresponding motor sequence.

In view of the present findings and earlier fMRI results, we propose that motor sequencing impairments resulting from premotor lesions reflect a sequence processing deficit rather than a motor deficit (if primary motor cortices are functionally intact). The disintegration of serially organized movements has been reported as a result of premotor lesions (Derouesne, 1973; Lurija, 1966). Forms of sequencing deficits differ slightly with respect to premotor lesion sites. Premotor lesions that include parts of the SMA appear to impair sequential movements that are internally (memory based) rather than sensory guided and often involve interlimb

coordination (Dick, Benecke, Rothwell, Day, & Marsden, 1986; Lepage et al., 1999). Behavioral deficits caused by such lesions of subacute status are typically characterized by paresis of the proximal muscles (shoulder and hip) contralateral to the lesion side, along with deficits in interlimb coordination (Freund, 1985, 1990; Freund & Hummelsheim, 1984, 1985). In contrast, lesions confined to the lateral premotor cortex impair sensory-guided sequential movement (Halsband & Freund, 1990; Halsband, Ito, Tanji, & Freund, 1993; Halsband et al., 2001). These findings have been taken as support for a suggested dichotomy between externally and internally guided sequencing involving lateral and medial premotor sites, respectively (Mushiake, Inase, & Tanji, 1991).

Finally, sequencing disorders are one of the main indicators of apraxia, a deficit that often follows damage to either parietal or premotor regions (Harrington & Haaland, 1992; Liepmann, 1920). Several subtypes of such sequencing deficits in the planning and programming of volitional acts have been described, including limb-kinetic apraxia (Brown, 1972) and ideomotor apraxia (Kimura, 1982; Motomura, Seo, Asaba, & Sakai, 1989; Rushworth, Nixon, Renowden, Wade, & Passingham, 1997). Most prominent are sequencing deficits in apraxia of speech, which is a loss of the capacity to program the positioning of the speech musculature and the sequencing of muscle movements during volitional production of phonemes (Darley, Aronson, & Brown, 1969). Disintegration of learned articulatory gestures in speech apraxia has been specifically attributed to damage within the left PMv region (Schiff, Alexander, Naeser, & Galaburda, 1983; Ziegler, 2002).

In line with the literature on monkeys, the present findings support the view that PMv functions provide a platform for both motor and sensory representations as well as their linkage. We have proposed that this linkage represents a short-term forward model that can specify parameters of different anticipatory behavior that may not result in overt motor output. Such a model may underlie both planning (internally guided sequencing) and prediction (externally guided sequencing) either with or without motor output (Schubotz et al., 2003).

References

- Aziz-Zadeh, L., Maeda, F., Zaidel, E., Mazziotta, J., & Iacoboni, M. (2002). Lateralization in motor facilitation during action observation: A TMS study. *Experimental Brain Research*, *44*, 127-131.
- Brown, A. W. (1972). *Aphasia, apraxia and agnosia: Clinical and theoretical aspects*. Springfield, IL: Charles C Thomas.
- Chaminade, T., Meary, D., Orliaguet, J. P., & Decety, J. (2001). Is perceptual anticipation a motor simulation? A PET study. *NeuroReport*, *12*, 3669-3674.
- Darley, F. L., Aronson, A. E., & Brown, J. R. (1969). Clusters of deviant speech dimensions in the dysarthrias. *Journal of Speech and Hearing Research*, *12*, 246-269.
- Derouesne, C. (1973). Le syndrome pré-moteur: A propos de 5 observations de tumeurs rolando-prérolandiques circonscrites [The premotor syndrome: A propos of 5 cases of circumscribed rolando-prerolandic tumors]. *Revue Neurologique Paris*, *128*, 353-363.
- Dick, J. P., Benecke, R., Rothwell, J. C., Day, B. L., & Marsden, C. D. (1986). Simple and complex movements in a patient with infarction of the right supplementary motor area. *Movement Disorders*, *1*, 255-266.

- Fogassi, L., Gallese, V., Buccino, G., Craighero, L., Fadiga, L., & Rizzolatti, G. (2001). Cortical mechanism for the visual guidance of hand grasping movements in the monkey: A reversible inactivation study. *Brain*, *124*, 571–586.
- Fogassi, L., Gallese, V., Fadiga, L., Luppino, G., Matelli, M., & Rizzolatti, G. (1996). Coding of peripersonal space in inferior premotor cortex (area F4). *Journal of Neurophysiology*, *76*, 141–157.
- Freund, H. J. (1985). Clinical aspects of premotor function. *Behavioural Brain Research*, *18*, 187–191.
- Freund, H. J. (1990). Premotor area and preparation of movement. *Revista de Neurologia*, *146*, 543–547.
- Freund, H. J., & Hummelsheim, H. (1984). Premotor cortex in man: Evidence for innervation of proximal limb muscles. *Experimental Brain Research*, *53*, 479–482.
- Freund, H. J., & Hummelsheim, H. (1985). Lesions of premotor cortex in man. *Brain*, *108*, 697–733.
- Gordon, A. M., Flament, D., Lee, J. H., Ugurbil, K., Kim, S. G., & Ebner, T. J. (1995). Functional MRI of cortical motor areas during sequential typing movements. *Proceedings of the Annual Conference of the Cognitive Science Society*, 1422.
- Grafton, S. T., Hazeltine, E., & Ivry, R. (1995). Functional mapping of sequence learning in normal humans. *Journal of Cognitive Neuroscience*, *7*, 497–510.
- Gregoriou, G. G., & Savaki, H. E. (2003). When vision guides movement: A functional imaging study of the monkey brain. *NeuroImage*, *19*, 959–967.
- Halsband, U., & Freund, H. J. (1990). Premotor cortex and conditional motor learning in man. *Brain*, *113*, 207–222.
- Halsband, U., Ito, N., Tanji, J., & Freund, H. J. (1993). The role of premotor cortex and the supplementary motor area in the temporal control of movement in man. *Brain*, *116*, 243–266.
- Halsband, U., Schmitt, J., Weyers, M., Binkofski, F., Grutzner, G., & Freund, H. J. (2001). Recognition and imitation of pantomimed motor acts after unilateral parietal and premotor lesions: A perspective on apraxia. *Neuropsychologia*, *39*, 200–216.
- Hanakawa, T., Honda, M., Sawamoto, N., Okada, T., Yonekura, Y., Fukuyama, H., & Shibasaki, H. (2002). The role of rostral Brodmann area 6 in mental-operation tasks: An integrative neuroimaging approach. *Cerebral Cortex*, *12*, 1157–1170.
- Harrington, D. L., & Haaland, K. Y. (1992). Motor sequencing with left hemisphere damage: Are some cognitive deficits specific to limb apraxia? *Brain*, *115*, 857–874.
- Hazeltine, E., Grafton, S. T., & Ivry, R. (1997). Attention and stimulus characteristics determine the locus of motor-sequence encoding. *Brain*, *120*, 123–140.
- Hikosaka, O., Miyashita, K., Miyachi, S., Sakai, K., & Lu, X. (1998). Differential roles of the frontal cortex, basal ganglia, and cerebellum in visuomotor sequence learning. *Neurobiology of Learning and Memory*, *70*, 137–149.
- Hikosaka, O., Sakai, K., Miyauchi, S., Takino, R., Sasaki, Y., & Pütz, B. (1996). Activation of human presupplementary motor area in learning of sequential procedures: A functional MRI study. *Journal of Neurophysiology*, *76*, 617–621.
- Honda, M., Deiber, M. P., Ibanez, V., Pascual-Leone, A., Zhuang, P., & Hallett, M. (1998). Dynamic cortical involvement in implicit and explicit motor sequence learning: A PET study. *Brain*, *121*, 2159–2173.
- Jänicke, H., Khoromskaia, V., Tittgemeyer, M., & Kruggel, F. (2002). Fast affine scaling of MR brain images with lesions. In *Annual Report 2002 of the Max Planck Institute of Cognitive Neuroscience* (p. 105). Retrieved from <http://www.cns.mpg.de/publikationen/annual/resources/AnnualReport2002.pdf>
- Kimura, D. (1982). Left-hemisphere control of oral and brachial movements and their relation to communication. *Philosophical Transactions of the Royal Society of London. Series B*, *298*, 135–149.
- Kurata, K., & Hoffman, D. S. (1994). Differential effects of muscimol microinjection into dorsal and ventral aspects of the premotor cortex of monkeys. *Journal of Neurophysiology*, *71*, 1151–1164.
- Lepage, M., Beaudoin, G., Boulet, C., O'Brien, I., Marcantoni, W., Bourgoin, P., & Richer, F. (1999). Frontal cortex and the programming of repetitive tapping movements in man: Lesion effects and functional neuroimaging. *Cognitive Brain Research*, *8*, 17–25.
- Liepmann, H. (1920). Apraxie [Apraxia]. In T. Brugsch & A. Eulenberg (Eds.), *Real-encyclopädie der gesamten heilkunde. Ergebnisse der gesamten medizin* [Encyclopedia of medical science]. (Vol. 1, pp. 116–143). Berlin, Germany: Urban & Schwarzenberg.
- Lurija, A. R. (1966). *Higher cortical functions in man*. New York: Basic Books.
- Motomura, N., Seo, T., Asaba, H., & Sakai, T. (1989). Motor learning in ideomotor apraxia. *International Journal of Neuroscience*, *47*, 125–129.
- Murata, A., Fadiga, L., Fogassi, L., Gallese, V., Raos, V., & Rizzolatti, G. (1997). Object representation in the ventral premotor cortex. *Journal of Neurophysiology*, *78*, 2226–2230.
- Murata, A., Gallese, V., Kaseda, M., & Sakata, H. (1996). Parietal neurons related to memory-guided hand manipulation. *Journal of Neurophysiology*, *75*, 2180–2186.
- Mushiaki, H., Inase, M., & Tanji, J. (1991). Neuronal activity in the primate premotor, supplementary, and precentral motor cortex during visually guided and internally determined sequential movements. *Journal of Neurophysiology*, *66*, 705–718.
- Nissen, M. J., & Bullemer, P. (1987). Attentional requirements of learning: Evidence from performance measures. *Journal of Cognitive Psychology*, *19*, 1–32.
- Passingham, R. E. (1985). Premotor cortex: Sensory cues and movement. *Behavioural Brain Research*, *18*, 175–185.
- Passingham, R. E. (1988). Premotor cortex and preparation for movement. *Experimental Brain Research*, *70*, 590–596.
- Ramrani, N., Toni, I., Josephs, O., Ashburner, J., & Passingham, R. E. (2000). Learning- and expectation-related changes in the human brain during motor learning. *Journal of Neurophysiology*, *84*, 3026–3035.
- Rizzolatti, G., Fogassi, L., & Gallese, V. (2000). Cortical mechanisms subserving object grasping and action recognition: A new view on the cortical motor functions. In M. S. Gazzaniga (Ed.), *The new cognitive neurosciences* (pp. 539–552). Cambridge, MA: MIT Press.
- Rizzolatti, G., Fogassi, L., & Gallese, V. (2002). Motor and cognitive functions of the ventral premotor cortex. *Current Opinion in Neurobiology*, *12*, 149–154.
- Rushworth, M. F., Nixon, P. D., Renowden, S., Wade, D. T., & Passingham, R. E. (1997). The left parietal cortex and motor attention. *Neuropsychologia*, *35*, 1261–1273.
- Sadato, N., Campbell, G., Ibanez, V., Deiber, M., & Hallett, M. (1996). Complexity affects regional cerebral blood flow change during sequential finger movements. *Journal of Neuroscience*, *16*, 2691–2700.
- Sakai, K., Hikosaka, O., Miyauchi, S., Takino, R., Sakaki, Y., & Pütz, B. (1998). Transition of brain activation from frontal to parietal areas in visuomotor sequence learning. *Journal of Neuroscience*, *18*, 1827–1840.
- Sakata, H., & Taira, M. (1994). Parietal control of hand action. *Current Opinion in Neurobiology*, *4*, 847–856.
- Sakata, H., Taira, M., Murata, A., & Mine, S. (1995). Neural mechanisms of visual guidance of hand action in the parietal cortex of the monkey. *Cerebral Cortex*, *5*, 429–438.
- Schieber, M. H. (2000). Inactivation of the ventral premotor cortex biases the laterality of motoric choices. *Experimental Brain Research*, *130*, 497–507.
- Schiff, H. B., Alexander, M. P., Naeser, M., & Galaburda, A. M. (1983). Aphemia: Clinical-anatomic correlations. *Archives of Neurology*, *40*, 720–727.
- Schubotz, R. I. (1999). Instruction differentiates the processing of temporal and spatial sequential patterns: Evidence from slow wave activity in humans. *Neuroscience Letters*, *265*, 1–4.

- Schubotz, R. I., Friederici, A. D., & von Cramon, D. Y. (2000). Time perception and motor timing: A common cortical and subcortical basis revealed by fMRI. *NeuroImage*, *11*, 1–12.
- Schubotz, R. I., & von Cramon, D. Y. (2001a). Functional organization of the lateral premotor cortex: fMRI reveals different regions activated by anticipation of object properties, location and speed. *Cognitive Brain Research*, *11*, 97–112.
- Schubotz, R. I., & von Cramon, D. Y. (2001b). Interval and ordinal properties of sequences are associated with distinct premotor areas. *Cerebral Cortex*, *11*, 210–222.
- Schubotz, R. I., & von Cramon, D. Y. (2002a). A blueprint for target motion: fMRI reveals perceptual complexity to modulate a premotor-parietal network. *NeuroImage*, *16*, 920–935.
- Schubotz, R. I., & von Cramon, D. Y. (2002b). Dynamic patterns make the premotor cortex interested in objects: Influence of stimulus and task revealed by fMRI. *Cognitive Brain Research*, *14*, 357–369.
- Schubotz, R. I., & von Cramon, D. Y. (2002c). Predicting perceptual events activates corresponding motor schemes in lateral premotor cortex: An fMRI study. *NeuroImage*, *15*, 787–796.
- Schubotz, R. I., von Cramon, D. Y., & Lohmann, G. (2003). Auditory what, where, and when: A sensory somatotopy in lateral premotor cortex. *NeuroImage*, *20*, 173–185.
- Taira, M., Mine, S., Georgopoulos, A. P., Murata, A., & Sakata, H. (1990). Parietal cortex neurons related to the visual guidance of hand movement. *Experimental Brain Research*, *83*, 29–36.
- Talairach, J., & Tournoux, P. (1988). *Co-planar stereotaxis atlas of the human brain*. New York: Thieme.
- Toni, I., Krams, M., Turner, R., & Passingham, R. E. (1998). The time course of changes during motor sequence learning: A whole-brain fMRI study. *NeuroImage*, *8*, 50–61.
- Vallar, G. (1993). The anatomical basis of spatial hemineglect in humans. In I. H. Robertson & J. C. Marshall (Eds.), *Unilateral neglect: Clinical and experimental studies* (pp. 211–231). Hove, England: Erlbaum.
- Ziegler, W. (2002). Psycholinguistic and motor theories of apraxia of speech. *Seminars in Speech and Language*, *23*, 231–244.

Received April 11, 2003

Revision received October 14, 2003

Accepted October 20, 2003 ■